

Cranio-Cerebral Injury due to Ocular Impalement: An Unusual Case Report

Prateek Rastogi*, Jenash Acharya**, Raghavendra Babu Y.P.*

Abstract

Injury to skull and its contents due to direct or indirect trauma is a common occurrence as well as cause of death in majority of accidents. We present a case wherein an industrial worker suffered penetrating ocular injury resulting in cranial trauma and death. The heated iron rod penetrated the eye, travelled below upwards from front to back, fractured the roof of orbit, causing penetrating injury to the brain. This case recommends use of protective eye gear for all workers in hazardous jobs.

Keywords: Ocular trauma; Brain injury; Industrial accident.

Introduction

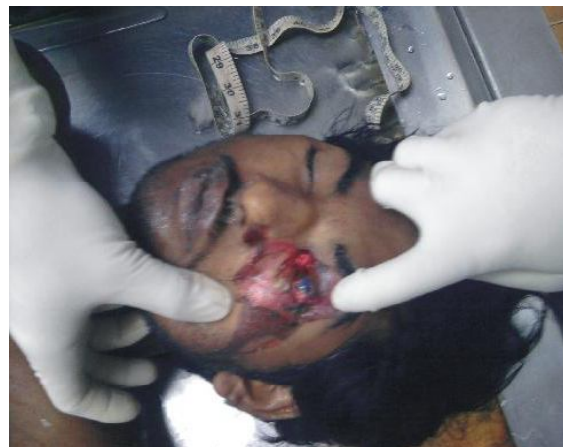Penetrating ocular injuries and their complications are routinely dealt by surgeons around the world. Ocular injuries pertaining to trauma to lens, conjunctiva, cornea, orbit and about treatment and surgical modalities for it can time and again be cited in literature. However, it goes beyond the hands of any human being if not a treating doctor when the force and direction of the penetrating object is such that it perforates the eyeball and causes injury to posterior structures as deep as brain resulting in immediate death of any individual. We present such a case where an industrial worker in iron manufacturing company sustained perforating injury to the eyeball resulting in immediate death.

Case History

As per the history given by the investigating officer, the deceased was a laborer in a steel and iron welding mill. One day when he was on duty a heated iron rod penetrated into his left eye while working on it. It was also mentioned that they had no doubt of foul play involved and it was a clear case of industrial accident. The 21 years adult was then rushed to nearby hospital where he succumbed to death prior to seeking any medical attention. The cause of death as furnished by the investigating officers was death due to penetration of iron rod into face.

At autopsy, a burn injury, measuring 10x5cm over the left eye involving left ala of

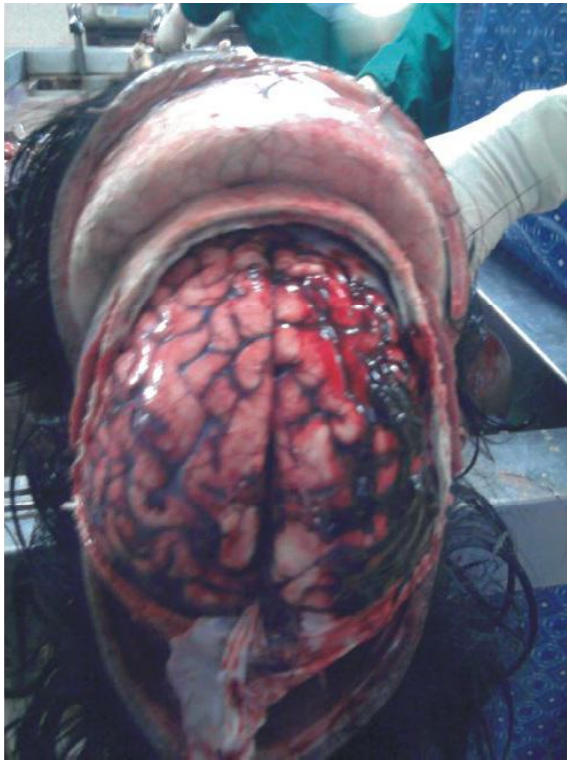Fig 1: Ocular Injury



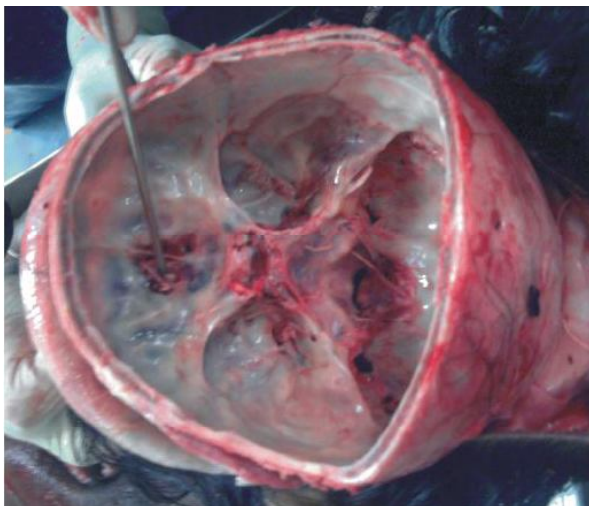
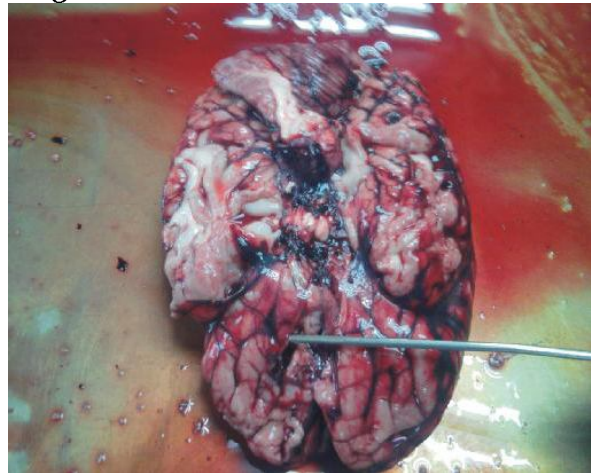
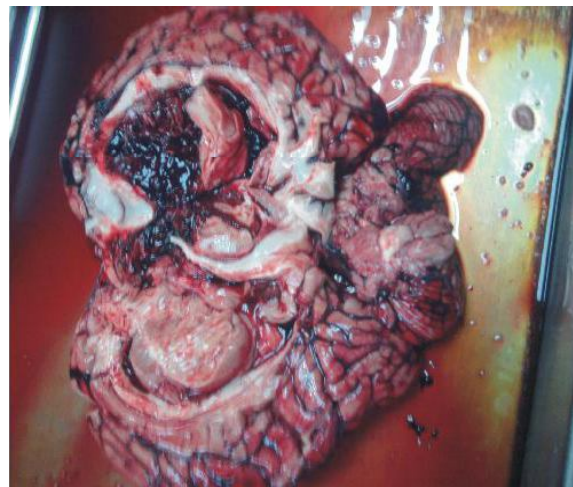Authors affiliation: Associate Professor, **Resident, Dept. of Forensic Medicine & Toxicology, Kasturba Medical College, Mangalore (Manipal University), Karnataka, India.

Reprints requests: Dr. Prateek Rastogi, Associate Professor, Department of Forensic Medicine & Toxicology, Kasturba Medical College, Light House Hill Road, Mangalore-575001, Karnataka, India.

E-mail: rastogiprateek@rediffmail.com,
prateek.rastogi@manipal.edu

Fig 2: Injury to the Brain

nose and left side of face and zygoma was noted overlying which was a penetrating laceration (Fig 1). Left cornea was opaque in appearance. Another superficial burn injury measuring 7x2cms was horizontally present at back of left forearm, 4 cm below the left elbow joint. Internal examination revealed sub-scalpal contusion over left supra-orbital region & Sub-dural and sub arachnoid hemorrhage over right cerebral hemisphere (Fig 2). On

Fig 3: Fracture of Anterior Cranial Fossa**Fig 4: Trauma to Undersurface of Brain****Fig 5: Damage to the Basal ganglia**

reflecting the frontal lobes of the brain, roof of left orbit (anterior cranial fossa) showed a perforating fracture at base of the skull (Fig 3) overlying which was a penetrating injury on the undersurface of softened frontal lobe (Fig 4). On further dissection, it was revealed that right basal ganglia were contused along with evident right intra-ventricular hemorrhage and pontine hemorrhage (Fig 5).

No other specific findings were noted in other internal organs except for congestion. Inner wall of left ventricle showed sub-endocardial hemorrhage and stomach contained greenish coloured mucoid fluid without any abnormal odour. The cause of death was given as cranio-cerebral injury sustained as a result of penetrating trauma to the left eye.

Discussion

Anatomical classification of ocular trauma can be done based on injury confined to anterior segment, posterior segment, adnexa and orbit. It can again be classified into penetrating or perforating based on structure involved. If only one surface of an ocular structure is damaged it is a penetrating injury whereas involvement of two structures creating entry and an exit is defined as perforating injury or in common words "double penetrating" injuries.[1] The classification to ocular trauma ends here, but what we had found in our case was injury that was deeper to ocular injury. Ocular injuries in adults are usually an intentional insult in which males are more affected than females (4:1).[2,3,4] In pediatric group, which amount to 8-14% of all eye injuries; it's usually accidental and involves only one side.[5,6]

The heated iron rod had penetrated taking such an unusual route and direction that on perforating the eyeball it had further travelled from below to upwards and front to back, fracturing the roof of orbital plate and further beyond causing penetrating injury to base of the brain. This unusual case in which brain sustained penetrating injury by a heated iron metallic rod with no evident fracture on the exterior of skull vault is what makes this case worth reporting. It is also recommended that employers in hardware industries are to look

into providing proper safety eye gears which would not only save the employee's eyesight but their vision in life too.

References

1. P Kaiser, N Freidman, R Pineda. The Massachusetts Eye and Ear Infirmary Illustrated Manual of Ophthalmology, 2nd Edition. Philadelphia PA: Saunders; 2004, 112-13 and 152-153.
2. T Wong, BE Dlein, R Klein. The prevalence and 5-year incidence of ocular trauma. The Beaver Dam Eye Study. *Ophthalmology*. 107(12): 2196-202.
3. AL Dannenberg, LM Parver, RJ Brechner, L Khoo. Penetration eye injuries in the workplace. The National Eye Trauma System Registry. *Arch Ophthalmol*. 110: 843-848.
4. AL Dannenberg, LM Parver, C J Fowler. Penetrating eye injuries related to assault. The National Eye Trauma System Registry. *Arch Ophthalmol*. 110: 849-852.
5. PV Scribano, M Nance, P Reilly *et al*. Paediatric nonpowder firearm injuries: Outcomes in an urban paediatric setting. *Paediatrics*. 1997; 100: E5.
6. JV Takvam, A Midelfort. Survey of eye injuries in Norwegian children. *Acta Ophthalmol (Copenh)*. 1993; 71: 500-5.